

## CLINICAL DATA SERIES IN BIORESORBABLE TECHNOLOGIES

Humberto Lamoutte, M.D., FACOG

Chairman, Dept. of Obstetrics and Gynecology  
Provena Saint Joseph Hospital Elgin, Illinois

Raja Chatterji, M.D., FACOG

Assistant Chairman, Dept. of Obstetrics and Gynecology  
Sherman Hospital Elgin, Illinois

# Controlling Soft-Tissue Attachments

The SurgiWrap® Bioresorbable Sheet is a valuable new addition to the armamentarium of gynecologic surgeons. Introduced in the United States in 2001, this polymeric sheet has many uses in both open and laparoscopic procedures, providing temporary wound support and reinforcing weakened soft tissues (Figures 1 through 4). Most important, this bioresorbable sheet creates a physical barrier between opposing tissues, which controls and minimizes the formation of soft-tissue attachments (STAs).

STAs, the fibrous bands that can form between a device and viscera or other tissues after gynecologic surgery, are often caused by ischemia, abrasion, desiccation, heat, electrocautery, or suturing. Forming within 1 to 2 months of surgery,<sup>1</sup> STAs may complicate future operations by increasing the risk of visceral perforation, extending operating time, and increasing postoperative pain.<sup>2-6</sup> They can lead to infertility, pelvic pain, and bowel obstruction.<sup>7-11</sup>

### SAFETY AND EFFICACY OF BIORESORBABLE SHEETS

#### Studies of the animal model

On-going reports demonstrate the utility of bioresorbable sheets for preventing adverse soft tissue outcomes. The preliminary results of 2 investigations in the animal model support preclinical observations, demonstrating that the use of bioresorbable sheets (SurgiWrap® MAST Biosurgery, San Diego, Calif) leads to at least a 2-fold reduction in the extent and severity of STAs when compared with untreated controls. The use of this product also maintains surgical dissection planes between the abdominal wall and adjacent soft tissues. Thus,

strategic placement of the bioresorbable sheets minimizes STA development during critical visceral healing.<sup>12,13</sup>

#### Case study series

Case reports from a number of clinicians have described the use of the bioresorbable sheet in gynecologic surgery to prevent STAs. Over 2 years, from September 2003 to September 2005, our team has placed the device in 180 patients to support the soft tissues and minimize STAs in patients who had cesarean deliveries. We have had the opportunity to reassess 11 patients during repeat cesarean deliveries (n=5), laparoscopic tubal ligations (n=2), lysis of adhesions for an ovarian cystectomy (n=1), hysterectomy (n=1), hysterectomy with left salpingo-oophorectomy (n=1), and resection of bilateral endometriomas (n=1).

The patient who came to us for treatment of bilateral endometriomas had extensive scar tissue. In an attempt to prevent further STAs, we wrapped bioresorbable sheets around each ovary. When the patient required an abdominal hysterectomy at a later time, we noted that no STAs had formed between the ovaries and the posterior wall. No residual SurgiWrap was found in the pelvis, and the cul-de-sac was free of STAs. In the absence of STAs, the procedure was completed in under 1 hour.

Between September 2005 and November 2006, our team performed 135 cesarean deliveries in which we used bioresorbable sheets and reassessed 16 of these patients. Of this group, 13 had no STAs. Two women had “filmy” STAs (grade 1) that were easily removed by blunt dissection. One patient had multiple STAs.

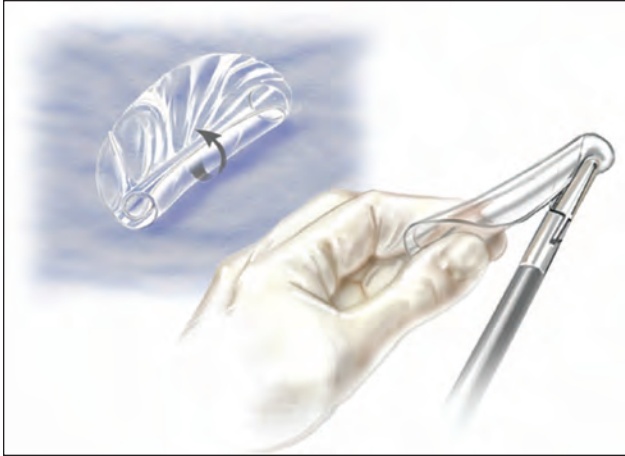


FIGURE 1.  
The sheet is wrapped around a blunt probe.

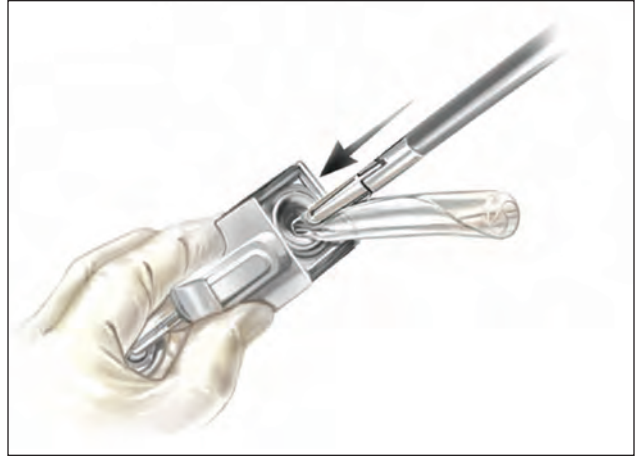

FIGURE 2.  
The thin transparent sheet is introduced through the 5mm trocar site.

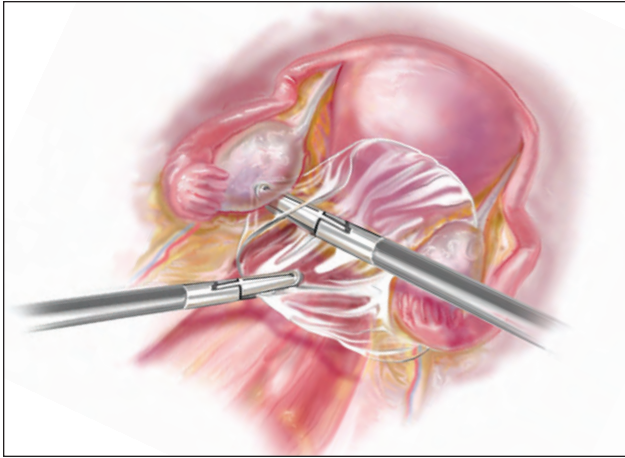


FIGURE 3.  
The sheet is then placed in the posterior cul-de-sac. In open procedures, the sheet is placed intraoperatively. In cesarean deliveries, it is placed after the uterine incision is closed. The bioresorbable sheet is easy to place after laparoscopic resection of endometriomas or lysis of adhesions.

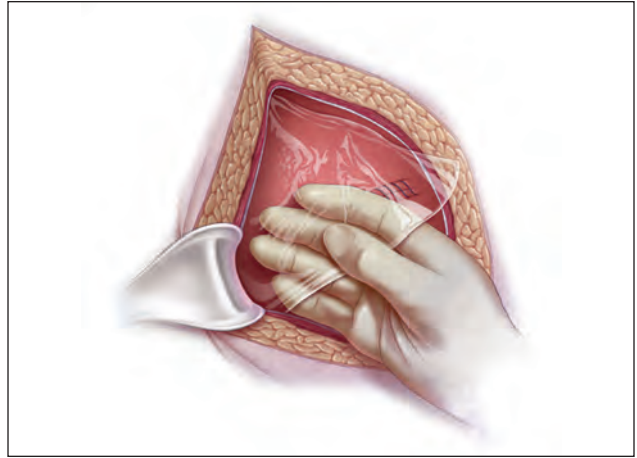


FIGURE 4.  
The sheet's transparent, thin profile allows for simplified intraoperative placement and good visualization of underlying tissues. The Bioresorbable Sheet should be used with resorbable sutures or other soft-tissue fixation devices that prevent dislocation.

Taking all of our case study series together, we have followed 354 patients in whom we have used SurgiWrap and conducted 37 re-looks. During the total duration of data collection, 4 adverse events were reported and documented, a rate of 1.1%.

### **SurgiWrap in 2 particular cases**

We followed a 39-year-old woman, gravida 4, para 4. Each of her deliveries had been cesarean; after her third delivery, STAs were found between the

omentum, bladder, and lower uterine segment. At that time, a bioresorbable sheet (SurgiWrap®) was placed over the uterus and bladder flap after the uterine incision was closed. This was done to reinforce the soft tissues, minimize STAs, and prevent recurrence of scar tissue. The sheet was held in place using 2 interrupted sutures through the rectus muscles and the device. At her fourth cesarean delivery a year and a half later, no STAs were found. We also reviewed a case of a 32-year-old patient,

gravida 3, para 2, with a 2-year history of pelvic pain, dysmenorrhea, and menorrhagia. An endometrial biopsy at the initial visit showed a secretory endometrium. A pelvic sonogram revealed bilateral complex adnexal masses, 3 cm in diameter, which were removed by ovarian cystectomy with endometrial ablation. The examination revealed enlarged ovaries adhered to the posterior uterine wall above the cul-de-sac. The ovarian capsules were opened to reveal bilateral endometriomas, which were later confirmed by pathologic testing. After the endometriomas were removed, the extensive STAs between the ovaries and uterus were excised with blunt and sharp dissection. The removal of these STAs resulted in multiple areas of minimal bleeding in the posterior uterine wall. To reinforce the soft tissues and control the attachment of soft tissues or development of recurring scar tissue, a bioresorbable sheet (SurgiWrap®) was placed into the abdomen through a 10-mm umbilical trocar. The device was positioned between the ovaries and uterus to support tissues, reduce the risk of attachment of surrounding tissues, and control the wound healing process. Endometrial ablation was performed.

The patient was placed on 6 months of therapy with gonadotropin-releasing hormone; an intramuscular contraceptive was eventually added to suppress ovarian function. The patient reported continued pain. A year after the initial surgery, a total abdominal hysterectomy with bilateral salpingo-oophorectomy was performed. At the time of surgery, no STAs were observed and no residual bioresorbable material was found in the pelvic area. The cul-de-sac area also had no STAs. Because of the absence of STAs, the surgical procedure was completed in less than 1 hour.

**ONGOING CLINICAL TRIALS**

A clinical study in Spain is currently evaluating the efficacy of 2 different bioresorbable sheets to minimize STA formation during endoscopic gynecologic surgery. In this comparison of SurgiWrap with processed regenerated cellulose (PRC) sheets, the primary effectiveness end point is the severity of attachment formation. Conducted by G.T. Lara, MD, and I.R. Ezcurra, MD, at the Hospital Virgen Del Camino, Unidad de Endoscopia Ginecologia in Pamplona, the study enrolled 31 patients from November 2003 to December 2004. None of the patients had undergone previous pelvic surgery. Most

of the patients in the study were schedule for either uterine cystectomy (myomectomy) or lysis of adherent adnexal tissue. At the end of the surgical procedure, 1 or both of the products were placed in regions of the uterine surface where the incision was performed: after lysis of tuboperitoneal obliterations, the device was place in the Douglas cavity and after lysis of attachments, it was placed next to adnexal organs.

To date, 6 patients have required adnexal surgery, allowing an opportunity for a second look at the products placed after the first procedure. A preliminary analysis was performed based on the assessment of the pelvic cavity, independent of the regions where the products were previously placed (Tables 1 and 2). Any new attachment formation was recorded and described with a defined grading system.

**CONCLUSIONS**

The use of the SurgiWrap® MAST Biosurgery bioresorbable sheets to control and minimize STAs by

**Attachment Formation: Bioresorbable Sheet vs PRC Sheet (Table 1):**

| Patient Number | Bioresorbable Sheet | PRC Sheet |
|----------------|---------------------|-----------|
| 8              | —                   | —         |
| 12             | —                   | ✓         |
| 14             | —                   | ✓         |

*PRC, processed regenerated cellulose. Attachments observed in second-look patients who received both the Bioresorbable Sheet and the PRC sheet (n=3).*

**Attachment Formation in the Presence of Bioresorbable Sheet (Table 2):**

| Patient Number | No Attachment | Filmy STA Bands |
|----------------|---------------|-----------------|
| 8              | ✓             | —               |
| 10             | —             | ✓               |
| 12             | ✓             | —               |
| 14             | ✓             | —               |
| 15             | ✓             | —               |

*PRC, processed regenerated cellulose. Attachments observed in second-look patients who received the Bioresorbable Sheet alone or in conjunction with the PRC sheet (n=5).*

creating a physical barrier between opposing weakened tissue represents an advancement in treatment options for gynecologic surgeons. The technical properties of the device — easily cut to meet various needs, pliable to permit use in various anatomies, and transparent to permit good visualization—make it appropriate for a variety of laparoscopic and open procedures.

## References

1. Elkins TE, Stovall TG, Warren J, et al. A histologic evaluation of peritoneal injury and repair: Implications for adhesion formation. *Obstet Gynecol.* 1987; 70:225-228.
2. Audebert AJ, Gornel V. Role of microlaparoscopy in the diagnosis of peritoneal and visceral adhesions and in the prevention of bowel injury associated with blind trocar insertion. *Fertil Steril.* 2000;73:631-635.
3. Van Der Krabben AA, Dijkstra FR, Nieuwenhuijzen M, et al. Morbidity and mortality of inadvertent enterotomy during adhesiotomy. *Br J Surg.* 2000; 87:467-471.
4. Sulaiman H, Gablela G, David C, et al. Presence and distribution of sensory nerve fibers in human peritoneal adhesions. *Ann Surg.* 2001;234:256-261.
5. Howard FM. Chronic pelvic pain. *Obstet Gynecol.* 2003;101:594-611.
6. Tulandi T, Collins JA, Burrows E, et al. Treatment-dependent and treatment-independent pregnancy among women with periadnexal adhesions. *Am J Obstet Gynecol.* 1990;1162:354-357.
7. Ellis H, Moran B, Thompson J, et al. Adhesion-related hospital readmissions after abdominal and pelvic surgery: a retrospective cohort study. *Lancet.* 1999;353:1496.
8. Al-Took S, Platt R, Tulandi T. Adhesion-related small bowel obstruction after gynecologic operations. *Am J Obstet Gynecol.* 1999;180:313-315.
9. Montz FJ, Holschneider CS, Solh S, et al. Small bowel obstruction following radical hysterectomy: risk factors, incidence, and operative findings. *Gynecol Oncol.* 1994;53:1114-1120.
10. Menzies D, Ellis H. Intestinal obstruction from adhesions—how big is the problem? *Ann R Col Surg Engl.* 1990;72:60-63.
11. Coleman MG, McLain AD, Moran BJ. Impact of previous surgery on time taken for incision and division of adhesions during laparotomy. *Dis Colon Rectum.* 2000;43:1297-1299.
12. Avital S, Bollinger TJ, Wilkinson JD, et al. Preventing intra-abdominal adhesions with polylactic acid film: an animal study. *Dis Colon Rectum.* 2005;48:153-157.
13. Walsh WR, Evans RO, Iliopoulos J, Cornwall GB, Thomas KA. Evaluation of a bioresorbable polylactide sheet for the reduction of pelvic soft tissue attachments in a porcine animal model. *J Biomed Mater Res B Appl Biomater.* 2006;79:166-175.